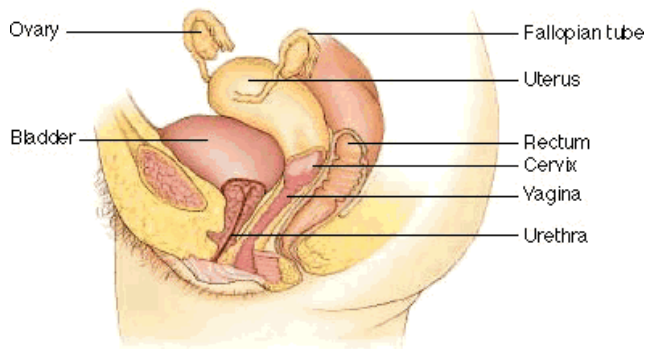




Anatomy of The Female Reproductive Organs

The female reproductive organs include the vagina (a muscular passage that connects the cervix with the external genital organs - one of which is a sensitive mound of tissue called the clitoris), the cervix (the lower part of the uterus that separates the body of the uterus from the vagina), the uterus (a hollow, muscular structure), the ovaries (two glands that produce certain hormones and contain tissue sacs in which eggs develop), and fallopian tubes (two muscular channels that connect the ovaries with the uterus). Fingerlike projections called fimbriae (located at the opening of the fallopian tubes) sweep an egg released from an ovary into the tube.

Cross-sectional view (Illustration provided by: Rolin Graphics)



Front view (Illustration provided by: DeEtte M. DeVille, M.D.)

